

Hodgkin's Lymphoma In Low-Income Countries: Experience Of Togo

Essohana Padaro¹, Kodzovi M C Womey^{1,*}, Yao Layibo², Kadara R Adandodo¹, Hèzouwè Magnang¹, Mensah D I Kueviakoe³

¹Hematology Department, Campus University Hospital Center, University of Lomé, Togo

²Hematology Laboratory, Sylvanus Olympio University Hospital Center, University of Lomé, Togo

³Hematology Laboratory, Tsévié Regional Hospital Center, University of Lomé, Togo

Abstract

While highly curable in developed countries, Hodgkin's lymphoma (HL), remains a significant challenge for resource-limited ones. This study aimed to describe the profile of HL in Togo. This was a retrospective, descriptive study conducted at the Clinical Hematology Department of the Campus University Hospital Center in Lomé, Togo. It focused on patient records diagnosed with HL between January 1, 2006, and December 31, 2022. Various variables such as age, gender, histological type of HL, Ann Arbor stage, prognostic classification, therapeutic protocol used, and patient outcomes were examined. The annual incidence of HL was 1.5 with a mean age of 38.7 years [range 12-63]. Lymph node enlargement was the primary clinical sign (100%). Histologically, classical HL was found in 21 patients (87.5%). Staging was conducted for 16 (66.7%) patients, among whom 11 (66.7%) were at an advanced stage, and 6 (37.5%) had an unfavorable prognosis. The ABVD protocol was used in 13 patients (54.2%), receiving between 1 and 6 cycles. One patient achieved complete remission (4.1%), three deceased (12.5%), and 17 (71%) were lost to follow-up. Hodgkin's lymphoma prognosis remains unfavorable with low remission rates in Togo. Improving the technical facilities will ensure better management of this lymphoma.

Research Article

Open Access &

Peer-Reviewed Article

DOI: 10.14302/issn.2372-6601.jhor-24-4962

Corresponding author:

Kodzovi M C Womey, Hematology Department, Campus University Hospital Center, University of Lomé, Togo

Keywords:

Hodgkin's lymphoma, epidemiology, Togo

Received: February 5, 2024

Accepted: March 3, 2024

Published: March 4, 2024

Academic Editor:

Rada M. Grubovic, Macedonia, the Former Yugoslav Republic of

Citation:

Essohana Padaro, Kodzovi M C Womey, Yao Layibo, Kadara R Adandodo, Hèzouwè Magnang et al. (2024) Hodgkin's Lymphoma In Low-Income Countries: Experience Of Togo. Journal of Hematology and Oncology Research - 4(3):24-30. <https://doi.org/10.14302/issn.2372-6601.jhor-24-4962>

Introduction

First reported by Thomas Hodgkin from the Guy's hospital in London in 1832, Hodgkin lymphoma are a family of unique lymphoma subtypes, in which the nature of the neoplastic cell was enigmatic for many years [1]. It's remains a distinct entity among lymphoproliferative neoplasms due to its biological characteristics [2]. It is characterized by nodal infiltration within a reactive tissue by voluminous tumor cells called Reed-Sternberg (RS) cells, essential for diagnosis but not entirely specific. The nature of the Reed-Sternberg cell has long been debated, but it is now well-established that it's a neoplasm derived from B cells, in which the unique cellular microenvironment plays an important role in accurate diagnosis and pathobiology. [3]. The diagnosis of Hodgkin lymphoma in

the modern era relies on an appropriate clinical setting, and morphological and immunophenotypic assessment [1]. Clinical and biological data from the last thirty years have distinguished two major entities in HL: classical HL and nodular lymphocyte-predominant HL [4]. It is a rare pathology but highly curable with well-defined recommendations based on various prognostic classifications and initial response to treatments, combining different chemotherapy protocol (ABVD, BEACOPP) and radiotherapy [5]. In Togo, patients do not always have access to prognostic tools, which are crucial for treatment strategies. Hence, we conducted this study to describe the epidemiological, clinical, biological, and therapeutic aspects of patients diagnosed with HL, as well as their outcomes in a resource-limited country like Togo. Additionally, this study aimed to assess the evolution of management, five years after the last one [6].

Methods

This was a retrospective, descriptive study involving patient records diagnosed with HL between January 1, 2006, and December 31, 2022, spanning a 16-year period. The study was conducted at the Clinical Hematology Department of CHU Campus in Lomé, Togo. The diagnosis of HL was based on histology from lymph node biopsy and/or immunohistochemistry. Staging included chest, abdominal and pelvis computed tomography and bone marrow biopsy in advanced stages. The Lugano Ann Arbor classification [7] was used to assess staging. The prognostic classifications used were the European Organization for Research and Treatment of Cancer (EORTC) [8] for limited stages and the International Prognostic Score (IPS) [9] for advanced stages.

Results

In total, 24 records were included. HL accounted for 18.1% of lymphoid neoplasms (24/132) and 3.8% of malignant hematologic disorders (24/748) during the study period. The annual incidence was 1.5. The mean age of patients was 38.7 years [12-63], with a male predominance and a sex ratio of 1.7. Figure 1 describes the distribution of patients by age group.

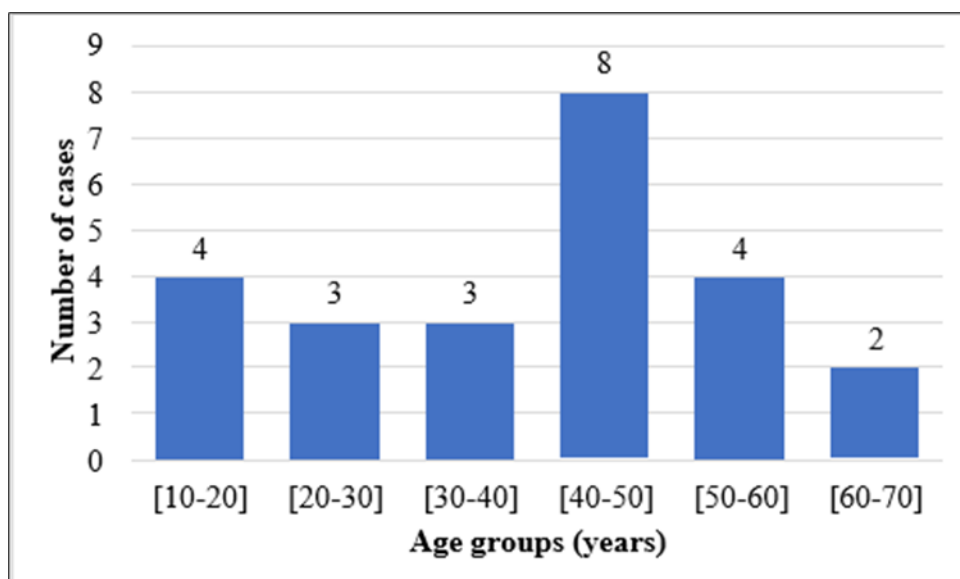


Figure 1. Distribution of patients according to age groups

Table 1. Distribution of cases according to histological types

	Numbers	Percentage
Classical HL	21	87,5
Nodular sclerosis HL	10	41,6
Mixed cellularity classical HL	6	25
Lymphocyte-rich classical HL	3	12,5
Lymphocyte-depleted classical HL	1	4,2
Not specified	1	4,2
Nodular lymphocyte predominant HL	3	12,5

The main presenting circumstance of Hodgkin's lymphoma (HL) was lymph node enlargement, present in all patients (100%). Patients also exhibited night sweats (6/24), prolonged fever (6/24), fatigue (1/24), and persistent pruritus (1/24). Physical signs were predominantly characterized by lymph node enlargement, averaging 7cm [range 2-15]. These were peripheral in 21 patients and cervical in 17. A quarter of the patients also presented with hepatomegaly, and four had splenomegaly.

Histologically, classical HL constituted most histological types, diagnosed in 21 (87.5%) patients. Table 1 illustrates the distribution of patients based on histology.

Sixteen patients underwent staging (66.7%). Among these patients, five (33.3%) were at an early stage

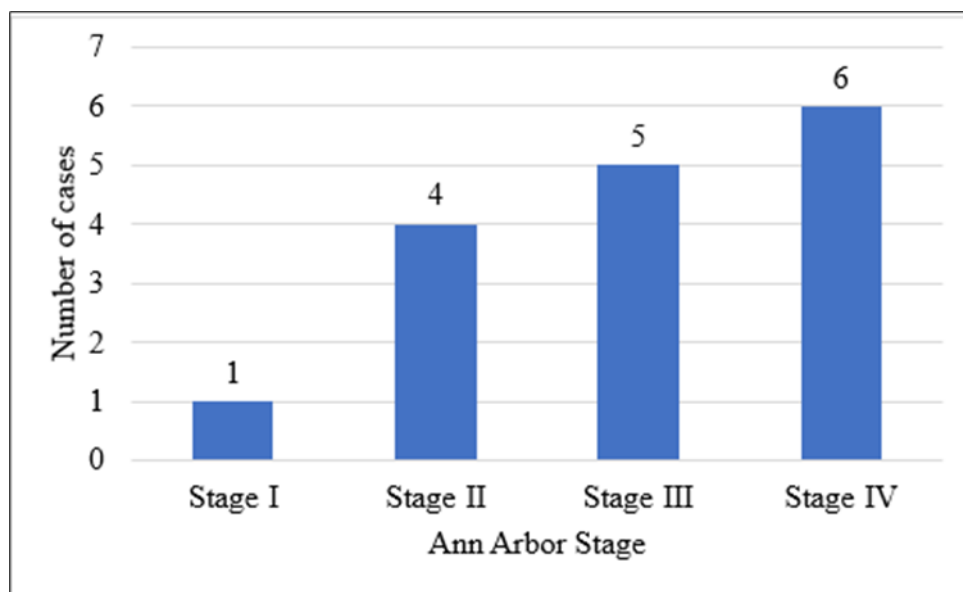


Figure 2. Distribution of patients according to Ann Arbor (Lugano) classification

Table 2. Distribution of patients according to prognostic classification

	Numbers	Percentage
EORTC Classification (Limited stage), n=5		
Favorable	4	80
Unfavorable	1	20

IPS Classification (Advanced stage), n=11		
Favorable	3	27,3
Unfavorable	8	72,7

Table 3. Distribution of patients according to their outcome

	Numbers	Percentage
Ongoing treatment	2	8,3
End of treatment	2	8,3
Partial remission	1	4,2
Complete remission	1	4,2
Deceased	3	12,5
Lost to follow-up	17	70,9

at diagnosis, with two patients presenting a bulky mass, and eleven (67.7%) were at an advanced stage (Figure 2). Adverse prognosis was observed in 37.5% of these patients (Table 2). Thirty-seven-point five percent (37.5%) of the included patients exhibited clinical signs of progression, and fifty-four percent (54%) showed biological signs of progression.

In terms of treatment, the frontline protocol used was the combination chemotherapy regimen of doxorubicin, bleomycin, vinblastine, and dacarbazine (ABVD). Thirteen patients, accounting for a ratio of 54.2%, initiated this treatment. They received between 1 and 6 cycles. Table 3 presents the outcomes of patients diagnosed with HL at the time of our study.

Discussion

In comparison to other malignant hematologic disorders, Hodgkin's lymphoma is relatively rare, as demonstrated by the prevalence found in our study. With approximately 1,500 new cases per year in France, Hodgkin's lymphoma accounts for only 10 to 15% of lymphomas and 0.5 to 1% of new cancer cases [10]. In the United States, it represents 10% of all lymphomas [11]. In Togo, although the incidence of Hodgkin's lymphoma is low, it is on the rise. While it was 0.65 new cases per year in a study conducted over a 20-year period by Padaro et al. [6], it is currently at 1.5. This increase could be attributed to an improvement in technical facilities and an increase in the number of pathologists, making diagnosis more accessible. Hodgkin's lymphoma exhibits a bimodal distribution, with an initial peak in young adults (20-30 years) and a second peak in individuals over 60 years old [12]. This bimodal incidence suggests that this pathology may stem from two distinct pathogenic processes: an infectious agent for young adults (EBV: Epstein Barr Virus) and a mechanism shared with other lymphomas for older patients [13,14]. In developing countries, Hodgkin's lymphoma predominantly affects a younger population. The average age of patients in our study aligns with this data, as do the findings of other sub-Saharan studies [15,16]. Hodgkin's lymphoma can also occur in children and adolescents, but it is rare before the age of 5 [12]. In our study, the low proportion of children found is explained by the fact that the hematology department at CHU Campus primarily receives adults. Male predominance has also been noted in previous series [11,17,18].

All patients presented with lymph node enlargement, predominantly peripheral and cervical. Indeed, at the time of diagnosis, most Hodgkin's lymphoma patients present with supradiaphragmatic

lymphadenopathy. Patients frequently exhibit involvement of cervical, anterior mediastinal, supraclavicular, and axillary lymph nodes, while inguinal regions are less commonly affected. About a third of patients present systemic symptoms such as fever, night sweats, and weight loss [19].

Classical HL is the most found subtype, accounting for nearly 90% of HL cases [17–19]. The results of our study align with this.

Only 16 patients (66.67%) underwent staging. This is mostly due to the patients' low socioeconomic status. Undergoing a scan cost approximately \$133 USD, approximately 2.3 times the minimum wage during the study period (\$58 USD). Long delays in specialized consultations, associated with diagnostic errors, and the difficulty in accessing the country's only public clinical hematology service account for the prevalence of advanced stages and poor prognoses in our study.

The indicated first-line treatment in our study was the ABVD protocol with six cycles, due to the unavailability of PET-CT at CHU and radiotherapy, which could have reduced the number of chemotherapy cycles based on the therapeutic response to systemic treatment. Only one patient achieved complete remission, and 17 (71%) were lost to follow-up. This high rate of loss to follow-up and low rate of remission reflects the financial precariousness of patients, most of whom did not initiate or complete the treatment. Indeed, Hodgkin's lymphoma is a highly curable hematologic malignancy, and the ABVD protocol is a validated treatment supported by several studies. It is used in combined therapy with radiotherapy or as a single modality due to the late toxicity of radiotherapy [20–22]. The BEACOPP protocol is another effective therapeutic alternative for advanced stages. However, it is more toxic, requiring additional supportive care and closer monitoring of hematological parameters [23–25], making it unfeasible in our practice setting. Therefore, therapeutic strategy in Hodgkin's lymphoma relies on effective risk stratification based not only on the Ann Arbor classification but also on certain prognostic factors [7,19]. Beyond the historical classifications of EORTC for limited stages and IPS for advanced stages [8,9], which have long guided therapeutic choices, PET-CT has proven useful both in diagnostic performance [26–29] and in treatment [30,31], leading to a modification in the therapeutic approach based on the response according to interim PET-CT after two cycles of chemotherapy. It is nowadays an indispensable tool for the effective management of Hodgkin's lymphoma.

Conclusion

Hodgkin's lymphoma is an infrequent lymphoma in our daily practice, even though its incidence is increasing. Its diagnosis is straightforward, relying on histology coupled with immunohistochemistry. Although the treatment is well-defined by various international recommendations, it poses similar challenges for practitioners in resource-limited countries, including prolonged diagnostic delays resulting in advanced disease and poor prognosis, inaccessibility to modern prognostic tools, and difficulty accessing standard or innovative therapies. All these factors lead to a low remission rate. Improvement in technical facilities and better social coverage will likely enable a more effective management of Hodgkin's lymphoma in Togo.

Conflicts of Interest: The authors declare no conflicts of interest.

References

1. Wang H-W, Balakrishna JP, Pittaluga S, Jaffe ES. Diagnosis of Hodgkin lymphoma in the modern

- era. *Br J Haematol.* 2019;184:45-59.
2. Weniger MA, Küppers R. Molecular biology of Hodgkin lymphoma. *Leukemia.* 2021;35:968-81.
 3. Swerdlow SH, Campo E, Pileri SA, Harris NL, Stein H, Siebert R, et al. The 2016 revision of the World Health Organization classification of lymphoid neoplasms. *Blood.* 2016;127:2375-90.
 4. Alaggio R, Amador C, Anagnostopoulos I, Attygalle AD, Araujo IB de O, Berti E, et al. The 5th edition of the World Health Organization Classification of Haematolymphoid Tumours: Lymphoid Neoplasms. *Leukemia.* 2022;36:1720-48.
 5. Howlader N, Noone AM, Krapcho M, Garshell J, Miller D, Altekruse SF, et al. SEER cancer statistics review, 1975–2012. *Natl Cancer Inst [Internet].* 2014 [cité 21 nov 2023]; Disponible sur: https://hero.epa.gov/hero/index.cfm/reference/details/reference_id/3420543
 6. Padaro E, Kueviakoe I, Magnang H, Layibo Y, Agbetiafa K, Mawussi K, et al. Caractéristiques épidémiologiques, clinico-biologiques, thérapeutiques et évolutives des patients atteints de la maladie de Hodgkin aux CHU de Lomé de 1999 à 2018. *Burkina Méd.* 2019;23:73-81.
 7. Bd C, Ri F, Sf B, F C, Lh S, E Z, et al. Recommendations for initial evaluation, staging, and response assessment of Hodgkin and non-Hodgkin lymphoma: the Lugano classification. *J Clin Oncol Off J Am Soc Clin Oncol [Internet].* 2014 [cité 21 nov 2023];32. Disponible sur: <https://pubmed.ncbi.nlm.nih.gov/25113753/>
 8. Diehl V, Stein H, Hummel M, Zollinger R, Connors JM. Hodgkin's lymphoma: biology and treatment strategies for primary, refractory, and relapsed disease. *Hematol Am Soc Hematol Educ Program.* 2003;225-47.
 9. Hasenclever D, Diehl V, Armitage JO, Assouline D, Björkholm M, Brusamolino E, et al. A Prognostic Score for Advanced Hodgkin's Disease. *N Engl J Med.* 1998;339:1506-14.
 10. Drouet F, Cahu X, Pointreau Y, Denis F, Mahé MA. Lymphome de Hodgkin. *Cancer/Radiothérapie.* 2010;14:S198-209.
 11. Miller KD, Nogueira L, Devasia T, Mariotto AB, Yabroff KR, Jemal A, et al. Cancer treatment and survivorship statistics, 2022. *CA Cancer J Clin.* 2022;72:409-36.
 12. Glaser SL, Jarrett RF. The epidemiology of Hodgkin's disease. *Baillieres Clin Haematol.* 1996;9:401-16.
 13. Punnett A, Tsang RW, Hodgson DC. Hodgkin Lymphoma Across the Age Spectrum: Epidemiology, Therapy, and Late Effects. *Semin Radiat Oncol.* 2010;20:30-44.
 14. Shenoy P, Maggioncalda A, Malik N, Flowers CR. Incidence Patterns and Outcomes for Hodgkin Lymphoma Patients in the United States. *Adv Hematol [Internet].* 2011 [cité 21 nov 2023];2011. Disponible sur: <https://www.ncbi.nlm.nih.gov/pmc/articles/PMC3010617/>
 15. Sawadogo D, Yapo A, Sangaré M, Tolo A, Yayo-Ayé M. Caractéristiques épidémiologiques des patients atteints d'hémopathies malignes à Abidjan au cours de la décennie 1995-2004. *J Afr Cancer.* 2009;1:4-10.
 16. Ngolet LO, Oval JDON, Dokekias AE. Les hémopathies lymphoïdes chroniques à Brazzaville. *Ann Sci Santé [Internet].* 2018 [cité 5 déc 2023];17. Disponible sur: <https://www.analesumng.org/index.php/ssa/article/view/261>
 17. Koffi KG, Sanogo I, Djigbenou D, Touré AH, Tolo A, N'Dhaz E, et al. Résultats du traitement de

62 cas de maladie de Hodgkin en Côte d'Ivoire. *Bull Soc Pathol Exot.* 2000;93:55-7.

18. Amégbor K, Darré T, Padaro E, Pegbessou EP, Bagny A, Napo-Koura G. Profil histopathologique et épidémiologique des lymphomes au Togo: à propos de 755 cas observés au CHU Tokoin de Lomé. *J Afr Cancer African J Cancer.* 2010;2:235-9.
19. Ansell SM. Hodgkin lymphoma: 2023 update on diagnosis, risk-stratification, and management. *Am J Hematol.* 2022;97:1478-88.
20. Ng AK. Current survivorship recommendations for patients with Hodgkin lymphoma: focus on late effects. *Blood.* 2014;124:3373-9.
21. Ng AK, Bernardo MVP, Weller E, Backstrand K, Silver B, Marcus KC, et al. Second malignancy after Hodgkin disease treated with radiation therapy with or without chemotherapy: long-term risks and risk factors. *Blood.* 2002;100:1989-96.
22. Hodgson DC, van Leeuwen FE. Second Malignancy Risk After Treatment of Hodgkin Lymphoma. In: Engert A, Younes A, éditeurs. *Hodgkin Lymphoma Compr Overv* [Internet]. Cham: Springer International Publishing; 2015 [cité 6 déc 2023]. p. 375-409. Disponible sur: https://doi.org/10.1007/978-3-319-12505-3_24
23. Bauer K, Skoetz N, Monsef I, Engert A, Brillant C. Comparison of chemotherapy including escalated BEACOPP versus chemotherapy including ABVD for patients with early unfavourable or advanced stage Hodgkin lymphoma. *Cochrane Database Syst Rev* [Internet]. 2011 [cité 21 nov 2023]; Disponible sur: <https://www.cochranelibrary.com/cdsr/doi/10.1002/14651858.CD007941.pub2/full>
24. André M, Bosly A. BEACOPPescalated versus ABVD in advanced Hodgkin's lymphoma. *Lancet Oncol.* 2013;14:911-2.
25. Wongso D, Fuchs M, Plütschow A, Klimm B, Sasse S, Hertenstein B, et al. Treatment-Related Mortality in Patients With Advanced-Stage Hodgkin Lymphoma: An Analysis of the German Hodgkin Study Group. *J Clin Oncol.* 2013;31:2819-24.
26. C A, T H, A D, S de G, T G, S LG, et al. 18-F FDG-PET in the staging of lymphocyte-predominant Hodgkin's disease. *Haematologica* [Internet]. 2008 [cité 21 nov 2023];93. Disponible sur: <https://pubmed.ncbi.nlm.nih.gov/18166797/>
27. A C, R D, Cr C, L T, M C, A G, et al. Initial staging of Hodgkin's disease: role of contrast-enhanced 18F FDG PET/CT. *Medicine (Baltimore)* [Internet]. 2014 [cité 21 nov 2023];93. Disponible sur: <https://pubmed.ncbi.nlm.nih.gov/25121354/>
28. Jf G, L V, T L, P M, C T, P W, et al. Performance of FDG PET/CT at initial diagnosis in a rare lymphoma: nodular lymphocyte-predominant Hodgkin lymphoma. *Eur J Nucl Med Mol Imaging* [Internet]. 2014 [cité 21 nov 2023];41. Disponible sur: <https://pubmed.ncbi.nlm.nih.gov/24965842/>
29. E B-M, J P, A S, B M, W K, E S, et al. Comparison of positron emission tomography/computed tomography with classical contrast-enhanced computed tomography in the initial staging of Hodgkin lymphoma. *Leuk Lymphoma* [Internet]. 2015 [cité 21 nov 2023];56. Disponible sur: <https://pubmed.ncbi.nlm.nih.gov/24794802/>
30. H N. Recent advances in Hodgkin lymphoma: interim PET and molecular-targeted therapy. *Jpn J Clin Oncol* [Internet]. 2015 [cité 21 nov 2023];45. Disponible sur: <https://pubmed.ncbi.nlm.nih.gov/25489004/>

31. Barrington SF, Phillips EH, Counsell N, Hancock B, Pettengell R, Johnson P, et al. Positron Emission Tomography Score Has Greater Prognostic Significance Than Pretreatment Risk Stratification in Early-Stage Hodgkin Lymphoma in the UK RAPID Study. *J Clin Oncol Off J Am Soc Clin Oncol.* 2019;37:1732-41.